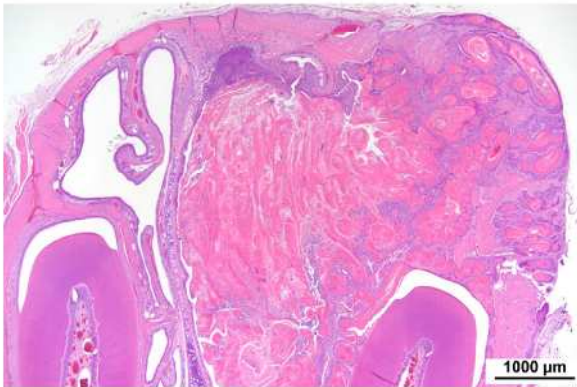


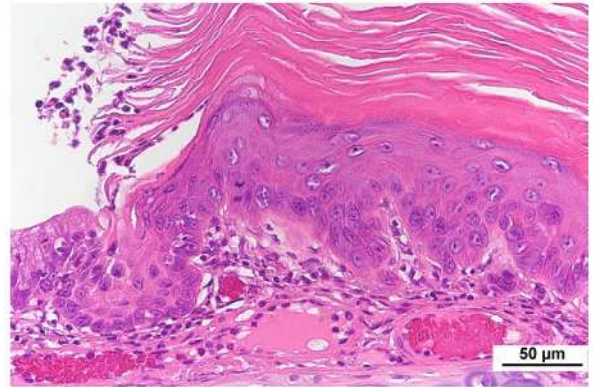
ブチルアルデヒドのラットを用いた
吸入によるがん原性試験報告書

試験番号：0914

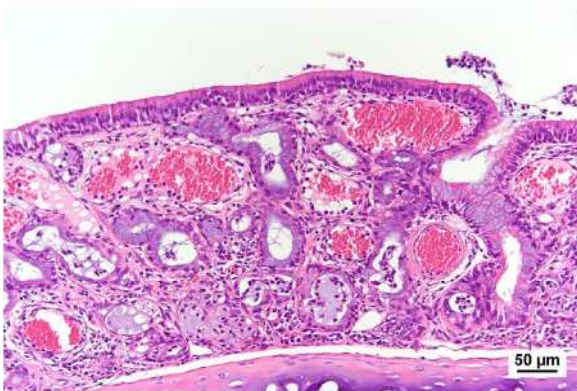
PHOTOGRAPHS



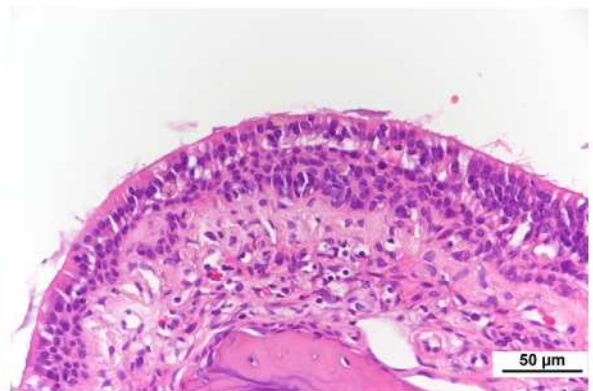
Photograph 1
Nasal cavity: Squamous cell carcinoma
Female, 3,000 ppm, Animal No. 0914-2315 (H&E)



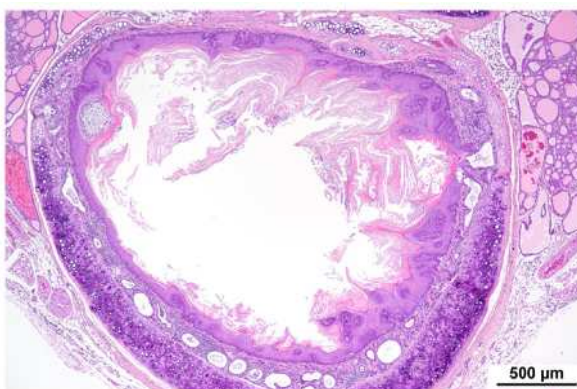
Photograph 2
Nasal cavity: Squamous cell hyperplasia, dysplastic
Male, 3,000 ppm, Animal No. 0914-1342 (H&E)



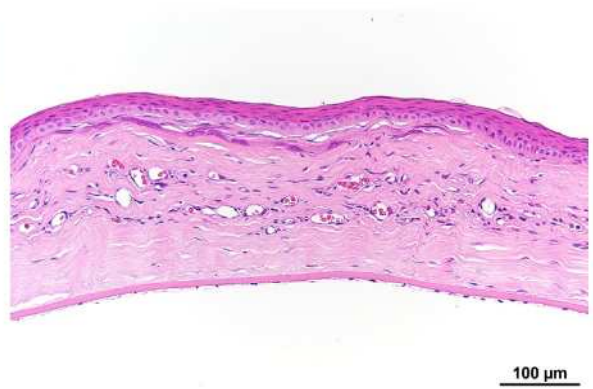
Photograph 3
Nasal cavity: Rhinitis
Male, 3,000 ppm, Animal No. 0914-1315 (H&E)



Photograph 4
Nasal cavity: Atrophy of olfactory epithelium and
Basal cell hyperplasia
Male, 3,000 ppm, Animal No. 0914-1306 (H&E)



Photograph 5
Trachea: Squamous cell hyperplasia
Male, 3,000 ppm, Animal No. 0914-1315 (H&E)



Photograph 6
Eye: Keratitis
Male, 300 ppm, Animal No. 0914-1132 (H&E)